

Testicular echotexture is not a viable method to indirectly evaluate the spermatogenic parameters in Nelore bulls

Wanessa Dias^a, Fábio J.C. Faria^a, Carlos A.C. Fernandes^b, Breno F.B. Sampaio^a, Marcelo D. Santos^c, Walvonvitis B. Rodrigues^a, Juliana C. Borges Silva^d, Deiler S. Costa^{a*}

ABSTRACT. The objective of this study was to evaluate the testicular echotexture of Nelore bulls and to correlate it with spermatogenic parameters. Forty one bulls aged 3-5 years, with body weight of 510.2 ± 21.61 kg were selected for the study. The animals were subjected to ultrasonography, using a portable device coupled with a linear transducer at a frequency of 7.5 MHz. Immediately afterwards they were castrated and the testicular tissue was treated with Karnovsky fixative. Next, the fragments were embedded in glycol methacrylate and stained with toluidine blue-1% sodium borate solution. The average pixel intensity in the testicular parenchyma was determined for 1,600-mm² surface sections. The right and left testicles and the area between the two testicles resulted in average pixel intensities of 105.22 ± 13.58 , 107.95 ± 12.82 , and 106.59 ± 11.43 , respectively. The efficiency coefficient of spermatogonial mitosis was 19.74; meiotic index was 2.63, and overall yield of spermatogenesis was 52.0. No correlation ($P > 0.05$) was observed between testicular echotexture and any of the measured morphometric parameters. These results suggest that testicular echotexture was not a viable method for the indirect analysis of cellular population in the seminiferous epithelium, intrinsic spermatogenic performance, or the Sertoli cell index in Nelore bulls.

Key words: testicular parenchyma, morphometry, ultrasonography, bovine.

RESUMEN. El objetivo de este estudio fue evaluar la ecotextura testicular de los toros Nelore y correlacionarlo con los parámetros de espermatogénesis. Para este propósito, 41 toros de edades de 3-5 años y con pesos corporales en el intervalo de $510,2 \pm 21,61$ kg fueron seleccionados para el estudio. Los toros se sometieron a ecografía, utilizando un dispositivo portátil junto con un transductor lineal a una frecuencia de 7,5 MHz. Inmediatamente después, los animales fueron castrados, y el tejido testicular se trató con Karnovsky fijador. Los fragmentos testiculares se incluyeron en metacrilato de glicol y se tiñeron con una solución de borato de sodio-azul de toluidina al 1%. La intensidad media de píxeles en el parénquima testicular se determinó para secciones de superficie de 1.600 mm². Los El área entre los dos testículos derecho e izquierdo dieron lugar a la intensidad media de los píxeles de $105,22 \pm 13,58$, $107,95 \pm 12,82$ y $106,59 \pm 11,43$, respectivamente. El coeficiente de eficiencia de la mitosis espermatogonial fue 19,74; Índice meiótico fue 2,63, y el rendimiento global del espermatogénesis alcanzó el 52,0. No se observó correlación ($P > 0,05$) entre ecotextura testicular y cualquiera de los parámetros morfométricos medidos. Estos resultados sugieren que ecotextura testicular no es un método viable para el análisis indirecto de la población celular en el epitelio seminífero, el rendimiento de la espermatogénesis intrínseco, o el índice de células de Sertoli en toros Nelore.

Palabras clave: parénquima testicular, morfometría, ultrasonografía, bovino.

INTRODUCTION

Testicular echotexture is analysed by computational analysis of the return intensity of ultrasonographic waves. Each pixel that composes the resulting image signifies one discrete reflection of the testicular parenchyma, the intensity of which may be quantified in 256 grayscale tones, from completely black (0) to completely white (256) (Singh *et al* 1998). This procedure can help to identify and objectively measure variations that cannot be seen with the naked eye; the quantitative computer algorithms that have been developed for this analysis therefore serve to eliminate the subjectivity inherent in visual analysis (Singh *et al* 2003).

Previous studies have attempted to correlate specific ultrasound features with testicular pathologies (Eilts and Pechman 1988), testicular degeneration due to insulation (Brito *et al* 2003, Arteaga *et al* 2005), daily sperm production and ejaculate quality (Kastelic *et al* 2001), testicular development (Silva *et al* 1997), and fibrotic injuries in the testicular parenchyma (Barth *et al* 2008). However, ultrasonography still has limited utility as a diagnostic tool in andrological examinations, most likely because research has shown little correlation between clinical results and testicular parenchyma echogenicity (Eilts and Pechman 1988, Brito *et al* 2003). However, despite contradictory preliminary results, it is thought that ultrasound will soon be an indispensable tool for animal breeders, similar to its application in gynecology (Siqueira and Viana 2006).

Spermatogenesis is a synchronous process, wherein a diploid spermatogonia differentiates itself into a highly specialised spermatozoon haploid cell. This process occurs in the seminiferous tubules, and usually lasts an average of 40-60 days in mammals (França and Russell 1998). According to Costa and Paula (2003), an understanding of spermatogenesis is necessary for breeders in order to achieve improved efficiency and outcomes.

Accepted: 08.09.2016.

^aFaculty of Veterinary Medicine and Animal Science, Federal University of Mato Grosso do Sul, Campo Grande, MS, Brazil.

^bUniversity of Alfenas, Veterinary College, Alfenas, MG, Brazil.

^cUniversity of Cuiabá, Veterinary College, Cuiabá, MT, Brazil.

^dEmbrapa Pantanal, Corumbá, MS, Brazil.

*Corresponding author: DS Costa; deilercosta@yahoo.com.br

The study of reproductive physiology in bulls would significantly benefit if a less-invasive and more reproducible method were developed to evaluate spermatogenesis. Currently, this analysis can only be accomplished through orchietomy or testicular biopsy. Orchietomy precludes any actual breeding, and is limited to scientific studies. On the other hand, testicular biopsy is still not the preferred choice by livestock owners despite its proven safety and the fact that it requires only 2-3 months before the tested animal regains full performance (Heath *et al* 2002).

Currently, there are no effective and widely accepted methods that can be used to determine daily sperm production in bulls. Significant differences in daily sperm production have been observed in sexually mature Zebu bulls (Andreussi *et al* 2014), therefore, a new method to track these differences would significantly improve breeding options.

The objective of the present study was to evaluate the testicular echotexture of the parenchyma and correlate it with spermatogenesis in Nelore bulls, specifically with respect to the cellular population of the seminiferous epithelium, intrinsic performance, and Sertoli cell (SC) index.

MATERIAL AND METHODS

ANIMALS

A total of 41 Nelore bulls were tested; all animals came from a single farm in the north-central region of the Brazilian state of Mato Grosso do Sul (latitude of 19°57'11" S; longitude of 54°53'33" W). The animals were aged 3 to 5 years and weighed 510.2 ± 21.61 kg. They were allowed to graze freely, and primarily had access to *Urochloa decumbens* and mineral salt. All animals were submitted to testicular examination, and there was no sign of clinical alterations such as degeneration, tumors, ectoparasites, asymmetries, or fibrosis.

All the experimental procedures were approved by the Ethics Committee for the Use of Animals of the Federal University of Mato Grosso do Sul (protocol number 623/2014).

ULTRASONOGRAPHIC EVALUATION OF THE TESTICULAR PARENCHYMA

The examinations were completed on the same day the animals were castrated by using a portable ultrasound device (Mindray DP 2200) coupled to a linear transducer with a frequency of 7.5 MHz. All measurements were performed by the same technician, and all device settings (including proximal, distal, and overall gains, focus area, brightness, and contrast) were set to default.

A gel was applied to the scan area, which was located vertically at the back of the scrotum, parallel to the major axis of each testicle. Each scan was completed using the minimal pressure necessary to capture the image (Arteaga *et al* 2005).

Still images were taken of the middle portion, between the mediastinum and the tunica albuginea, with as few artifacts as possible (resulting from refraction or dispersion or attenuation of the ultrasound waves). Images were recorded using the uncompressed .bmp file format, set to 256 grayscale tones.

The echotexture was quantified using ImageJ 1.34s software¹. After selecting a specific area of the testicular parenchyma, the software extracted the individual grayscale value. The selected areas were 1,600 mm² in size (figure 1), as recommended by Pinho *et al* (2013).

PREPARATION FOR HISTOLOGICAL ANALYSIS

After the animals were castrated, the epididymis was dissected and the testicular artery was cannulated and injected with a 0.9% saline solution containing 5000 IU of heparin/L of solution for at least 15 minutes at room temperature. Immediately afterwards, the testicles were suffused with Karnovsky fixative (4% paraformaldehyde and 5% glutaraldehyde in 0.1 M phosphate buffer for a final pH of 7.4) for 20 minutes, also at room temperature. The flasks containing these solutions were kept at a height of 120 cm above the testicles in order to maintain an approximate pressure of 80 mmHg (Costa *et al* 2004).

Testicular parenchyma fragments of approximately 8.0 x 5.0 x 3.0 mm in size were harvested from the middle third of the organ and fixed again by immersion in a new batch of Karnovsky fixative for more than 24 h. Then they were stored in phosphate buffer under refrigeration for no more than 5 days before processing.

The testicular parenchyma fragments were dehydrated in increasing concentrations of ethyl alcohol and then embedded in glycol methacrylate solution, according to Costa *et al* (2004). Finally, 4 µm sections were cut with a microtome equipped with a glass razor, then they were stained with toluidine blue 1% sodium borate solution. Finally, the slides were mounted with Entellan® (Merck), following standard techniques.

HISTOMETRIC EVALUATION OF THE SPERMATOGENIC PROCESS

The number of each cell type in seminiferous tubules was estimated by counting nuclei of germinative cells and nucleoli of Sertoli cells, in 30 cross sections of seminiferous tubules of symmetrical outline in stage 1 of the cycle of the seminiferous epithelium (CSE), classified using the tubular morphology method (Ortavant *et al* 1977). The following cell types were considered: type A spermatogonia (A), primary spermatocytes in preleptotene/leptotene (PL/L), primary spermatocytes

¹ Rasband W. 2005. National Institute of Health, USA. Software available at <http://rsb.info.nih.gov/ij/>; Accessed on 10/10/13.

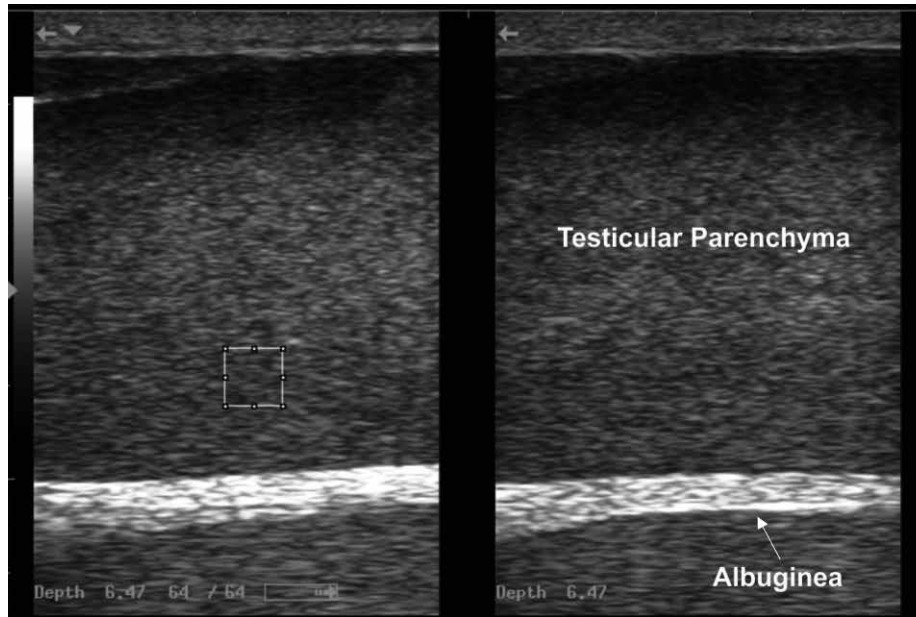


Figure 1. Ultrasound image of the testicular parenchyma of bull (ImageJ software). Square area = 1600 mm².

in pachytene (PC), round spermatids (RS) and Sertoli cells (SC). Numbers were corrected for mean nuclear diameter and slice thickness, using the Abercrombie (1946) formula modified by Amann (1962).

Mean nuclear or nucleolar diameter was determined for at least 15 nuclei in each type of germinative cell or 15 nucleoli in Sertoli cells, for CSE stage 1 in each animal. Because type A spermatogonia have ovoid or slightly elongated nuclei, the means of the largest and smallest nuclear diameters were used.

Cell populations were determined by counting each cell type with the aid of morphometry software ImageJ 1.34¹, using digitised microscopic images.

Measurements of nuclear diameters of germ cells and Sertoli cell nucleoli were also performed with the aid of this software.

The intrinsic rate of spermatogenesis was estimated from the ratio between corrected cell numbers, determined in stage 1 of the CSE. The following ratios were determined: efficiency coefficient of spermatogonial mitosis (PL/L:A), meiotic index (RS:PC), overall yield of spermatogenesis (RS:A) and cell loss during the meiotic prophase (PL/L:PC).

Analysis of ratios between numbers of germ cells and Sertoli cells in stage 1 of the CSE, or Sertoli cell index, included the following: A:SC, PL/L:SC, PC:SC, RS:SC and total germ cells:SC.

STATISTICAL ANALYSIS

Data were expressed as mean ± standard deviation. Pearson’s correlation was calculated for the parenchyma echotexture and the morphometric parameters. The

significance level was set at 5%. All analyses were conducted using the BioEstat 5.0 software.

RESULTS AND DISCUSSION

The corrected mean numbers of spermatogenic and Sertoli cells in transverse sections of seminiferous tubules during stage 1 of the CSE in Nelore bulls are presented in table 1. At this stage, the presence of type A spermatogonia and primary spermatocytes in pre-leptotene/leptotene were observed in the basal compartment of the seminiferous epithelium. Primary pachytene spermatocytes and round spermatids forming several layers were observed in the adluminal compartment (figure 2).

The values corresponding to the intrinsic rate of spermatogenesis are shown in table 2. The results showed that

Table 1. Number of cell types in stage 1 of the cycle of the seminiferous epithelium in Nelore bulls.

Cell type	Average ± SD
Sertoli cells	4.06 ± 0.50
Type A spermatogonia	1.90 ± 0.22
Primary spermatocytes in preleptotene/leptotene	36.87 ± 3.50
Primary spermatocytes in pachytene	36.83 ± 3.27
Round spermatids	96.97 ± 18.30

Numbers obtained from analyzing 20 cross-sections in the seminiferous tubules of each animal (n = 41). Corrected values as per Amann (1962). SD = standard deviation.

Table 2. Ratios between corrected numbers of germinative cells by transverse section of seminiferous tubules in stage 1 of the cycle of the seminiferous epithelium in Nelore bulls.

Cell types	Ratios*
Spermatocytes I in PL/L, type A spermatogonia	19.74 ± 3.19
Spermatocytes I in PC, spermatocytes I in PL/L	1.00 ± 0.04
Round spermatids, spermatocytes I in PC	2.63 ± 0.45
Round spermatids, type A spermatogonia	52.05 ± 12.37

PL/L = preleptotene/leptotene; PC = pachytene.

* Average ± standard deviation.

in Nelore bulls, each type A spermatogonia generated 19.74 primary spermatocytes in preleptotene/leptotene. No significant losses were observed during the meiotic prophase (i.e., the population of primary spermatocytes was kept constant during this phase).

The meiotic index, however, was 65.75% of the theoretically expected value in case of no losses during spermatogenesis. The number of round spermatids resulting from each type A spermatogonia was approximately 52.

The Sertoli cells (SC) index is presented in table 3. Note that each SC is capable of supporting, on average, about 43 germ cells.

The echotexture for the right and left testicles, as well as those for the average of the two, are correlated with the cellular populations in table 4, intrinsic performance in table 5, and the SC ratios in table 6. No significant correlations were observed.

The overall echotexture of each bull was homogenous and moderately echogenic. The average pixel intensity of the right and left testicular parenchyma and the area between the testicles was 105.22 ± 13.58, 107.95 ± 12.82, and 106.59 ± 11.43, respectively.

The observed homogeneity and echogenicity observed in this trial are consistent the reports of Pastore *et al* (2015) and Pinho *et al* (2013), who worked with Nelore bulls,

Table 3. Ratios between corrected numbers of germinative cells in stage 1 of the cycle of the seminiferous epithelium and Sertoli cells in Nelore bulls.

Cell types	Ratios*
Type A spermatogonia, Sertoli cell	0.47 ± 0.08
Spermatocytes I in preleptotene/leptotene, Sertoli cell	9.20 ± 1.33
Spermatocytes I in pachytene, Sertoli cell	9.19 ± 1.29
Round spermatids, Sertoli cell	24.04 ± 4.62
Total germinative cells, Sertoli cell	42.89 ± 6.32

* Average ± standard deviation.

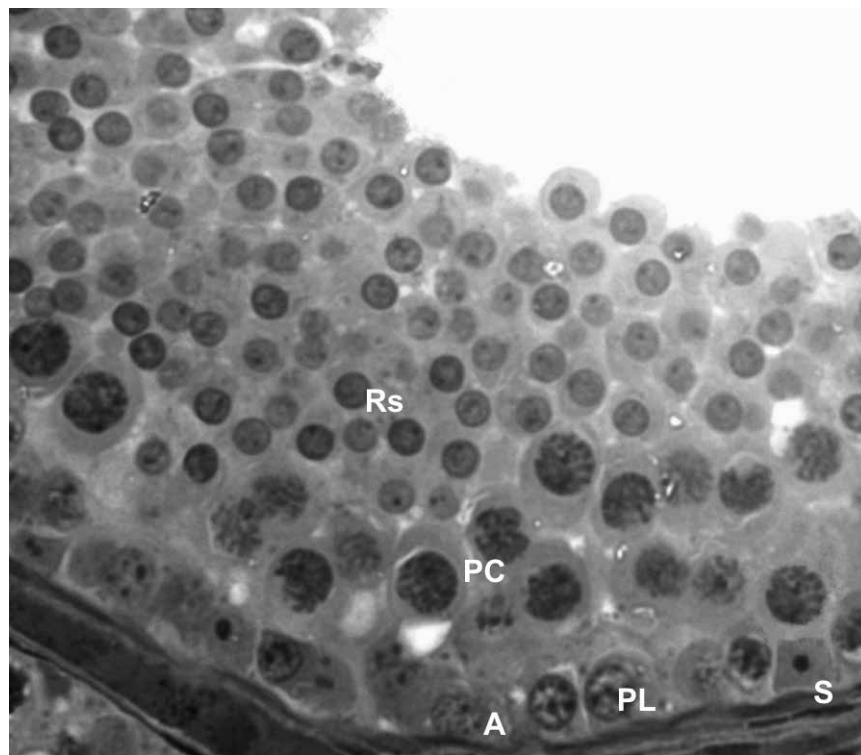


Figure 2. Cross-section of seminiferous tubule characterizing stage 1 of the seminiferous epithelium of orchectomied bull. A: type A spermatogonia, S: Sertoli cells, PL: primary spermatocytes in pre-leptotene, PC: primary spermatocytes in pachytene, Rs: round spermatids; Toluidine blue + sodium borate 1%. 400X magnification.

Table 4. Coefficients for the echotexture of the parenchyma of the right testicle (EcoRT), the left testicle (EcoLT), and both testicles (EcoMed) when correlated with cellular population in Nelore bulls.

	SC	A	PL/L	PC	RS
EcoRT	-0.053	0.155	-0.211	-0.110	-0.173
EcoLT	-0.082	-0.005	-0.273	-0.210	-0.131
EcoMed	-0.063	0.141	-0.209	-0.110	-0.173

SC = Sertoli cells; A = type A spermatogonia; PL/L = primary spermatocytes in preleptotene/leptotene; PQ = primary spermatocytes in pachytene; RS = round spermatids. Pearson's correlation ($P>0.05$)

Table 5. Coefficients for the echotexture of the parenchyma of the right testicle (EcoRT), the left testicle (EcoLT), and both testicles (EcoMed) when correlated with intrinsic rate of spermatogenesis in Nelore bulls.

	CSM	MI	OYS	CLP
EcoRT	-0.249	-0.125	-0.239	0.232
EcoLT	-0.236	0.095	-0.179	0.102
EcoMed	-0.238	-0.128	-0.233	0.231

CSM, Coefficient of spermatogonial mitosis. MI, Meiotic index. OYS overall yield of spermatogenesis. CLP, Cell loss during prophase. Pearson's correlation ($P>0.05$)

Table 6. Coefficients for the echotexture of the parenchyma of the right testicle (EcoRT), the left testicle (EcoLT), and both testicles (EcoMed) when correlated with Sertoli cells ratios in Nelore bulls.

	SC:A	SC:PL/L	SC:PC	SC:RS	SC:total
EcoRT	0.168	-0.150	-0.036	-0.196	-0.185
EcoLT	0.084	-0.095	-0.091	-0.112	-0.141
EcoMed	0.164	-0.145	-0.032	-0.194	-0.181

SC = Sertoli cells; A = type A spermatogonia; PL/L = primary spermatocytes in preleptotene/leptotene; PQ = primary spermatocytes in pachytene; RS = round spermatids. Total, Germ cell total. Pearson's correlation ($P>0.05$).

and the findings of Pechman and Eilts (1987) and Abdel-Razek and Ali (2005), who worked with Taurine cattle. In addition, no significant differences were observed in pixel intensities between the right and left testicles, reinforcing observations by Aravindakshan *et al* (2000), Cardilli *et al* (2009), and Pinho *et al* (2013). The observed homogeneity has already been reported in previous studies, in which fragments extracted from different sections of the testicle presented morphometric counts that were not significantly different from each other (Andreussi *et al* 2014).

The calculated average pixel intensity between the two testicles was equal to the value obtained by Pinho *et al* (2013), who worked with young Nelore bulls. This is reasonable considering that the bulls from both studies were already sexually mature, even if those used in this study were older than the ones investigated in the aforementioned one. Additionally, both experiments were carried out with very similar methodology; specifically, the same ultrasound device and settings were applied, and the same area was evaluated for pixel size.

Alternatively, Silva *et al* (1997) previously reported an average pixel intensity of 163.7 for 15.6 month old Nelore

bulls. Furthermore, Gabor *et al* (1998) obtained a value of 131.9 for 49 Holsteins that were between 16 and 19 months old. Brito *et al* (2003) found values of 196.1, 192.7, and 190.7 for Zebu, hybrid, and Taurine cattle, respectively. Moreover, Kastelic *et al* (2001) reported an intensity of 158.5 while working with Angus cattle, and Carmo *et al* (2012) analysed Guzarat cattle that were 21-24, 24.1-27, and 27.1-30 months old and obtained values of 102.3, 112.0, and 127.5, respectively. Pinho *et al* (2012) worked with Montana cattle, obtaining values of 95.7 and 94.0 for animals that could and could not reproduce, respectively. Finally, Cardilli *et al* (2012) worked with sexually mature 18 month old Nelore bulls and obtained a value of 115.3.

The previously cited research that studied various sexually mature Zebu cattle reported average values between 106.5 and 127.5. This variation can be attributed to differences in breeding and feeding (Pastore *et al* 2015), not to mention differences in ultrasound settings, which can produce different grayscale values and result in different echotextures. In other words, differences in methodology can result in different measurements, even for the same animal (Pinho *et al* 2013).

Kastelic *et al* (1997) worked with Canchim and Nelore cattle, as well as their hybrids, and observed that increased values in the echotexture pixel counts correlated with decreased sperm pathology. However, Gabor *et al* (1998) found opposing results, obtaining a correlation coefficient of $r = -0.48$ when comparing echotexture to the proportion of living spermatozoa in sexually mature Holsteins.

These contrasting results may be partially explained by the fact that ejaculated spermatozoa start being produced 70 days before being available, with 63 of those days being attributed to spermatogenesis and the remainder being needed for transit to the epididymis (Cosentino *et al* 1984).

To the best of our knowledge, there are no studies attempting to correlate testicular echotexture with spermatogenic morphometry in bovines. Therefore, it was impossible to compare our data with other work. Our laboratory had worked on a similar project in the past, in which the relationship between spermatogenesis and testicular echotexture was evaluated in Pantaneiro horses (unpublished data). The study assessed pixel intensity in stage 1 of CSE for 22 stallions between 3 and 6 years old, and only found correlations of $r = 0.4$ and $r = -0.5$ for the proportion of tubule lumen and for the population of Type A spermatogonia. No correlation was found for any other morphometric parameters ($P > 0.05$).

The observed tubule lumen correlation has also been indirectly reported in prepubertal and pubertal animals; pixel intensity increased with age which can be principally related to this parameter (Pechman and Eilts 1987, Aravindakshan *et al* 2000, Brito *et al* 2004, Abdel-Razek and Ali 2005, Pastore *et al* 2015).

Overall, contradictory results have been obtained when correlating testicular echotexture with reproductive elements such as spermatogenesis and semen quality (Kastelic *et al* 1997, Brito *et al* 2003, Pinho *et al* 2013). This complicates the introduction of ultrasound as a viable diagnostic alternative for breeding. The lack of any significant correlation in this study further highlights this problem in the case of sexually mature bulls.

In conclusion, the analysis of testicular echotexture was not a viable method to indirectly evaluate the cellular population in the seminiferous epithelium, intrinsic rate of spermatogenesis, or the Sertoli cells index of Nelore bulls.

ACKNOWLEDGEMENTS

The authors would like to thank the Fundação de Apoio ao Desenvolvimento do Ensino, Ciência e Tecnologia do Estado de Mato Grosso do Sul (FUNDECT) and CAPES for supporting this study.

REFERENCES

- Abdel-Razek A, Ali A. 2005. Developmental changes of bull (*Bos taurus*) genitalia as evaluated by caliper and ultrasonography. *Reprod Domest Anim* 40, 23-27.
- Abercrombie M. 1946. Estimation of nuclear populations from microtome sections. *Anat Rec* 94, 239-247.
- Amann RP. 1962. Reproductive capacity of dairy bulls. III. The effect of ejaculation frequency, unilateral vasectomy, and age on spermatogenesis. *Am J Anat* 110, 49-67.
- Andreussi PAT, Costa DS, Faria FJC, Fernandes CAC, Santos MD, *et al*. 2014. Testicular histomorphometric evaluation of Zebu bull breeds. *Braz Arch Biol Technol* 57, 900-907.
- Aravindakshan JP, Honaramooz A, Bartlewski PM, Beard AP, Pierson RA, *et al*. 2000. Pattern of gonadotropin secretion and ultrasonographic evaluation of developmental changes in the testis of early and late maturing bull calves. *Theriogenology* 54, 339-354.
- Arteaga AA, Barth AD, Brito LF. 2005. Relationship between semen quality and pixel-intensity of testicular ultrasonograms after scrotal insulation in beef bulls. *Theriogenology* 64, 408-415.
- Barth AD, Alisio L, Avilés M, Arteaga AA, Campbell JR, *et al*. 2008. Fibrotic lesions in the testis of bulls and relationship to semen quality. *Anim Reprod Sci* 106, 274-288.
- Brito LF, Silva AE, Barbosa RT, Unanian MM, Kastelic JP. 2003. Effects of scrotal insulation on sperm production, semen quality, and testicular echotexture in *Bos indicus* and *Bos indicus* x *Bos taurus* bulls. *Anim Reprod Sci* 79, 1-15.
- Brito LF, Silva AE, Unanian MM, Dode MA, Barbosa RT, *et al*. 2004. Sexual development in early- and late-maturing *Bos indicus* and *Bos indicus* x *Bos taurus* crossbred bulls in Brazil. *Theriogenology* 62, 1198-1217.
- Cardilli DJ, Toniollo GH, Pastore AA, Canola JC, Mercadante MEZ. 2009. Alterações do padrão ultrassonográfico do parênquima testicular em bovinos jovens da raça Nelore. *Acta Sci Vet* 37, 367-370.
- Cardilli DJ, Toniollo GH, Pastore AA, Canola JC, Oliveira JA, *et al*. 2012. Testicular ultrasonography in young Nelore bulls raised in extensive management system. *Arq Bras Med Vet Zootec* 64, 75-82.
- Carmo AS, Osorio JP, Mendonça LF, Lago LA, Henry M, *et al*. 2012. Aspectos biométricos y ultrasonográficos del desarrollo testicular en bovinos de la raza guzerat (*Bos taurus indicus*). *Rev Cienc Anim* 5, 51-62.
- Cosentino MJ, Takihara H, Burhop JW, Cockett AT. 1984. Regulation of rat caput epididymidis contractility by prostaglandins. *J Androl* 5, 216-222.
- Costa DS, Henry M, Paula TAR. 2004. Espermatogênese de Catetos (*Tayassu tajacu*). *Arq Bras Med Vet Zootec* 56, 46-51.
- Costa DS, Paula TAR. 2003. Espermatogênese em mamíferos. *Scientia* 4, 53-72.
- Eilts BE, Pechman RD. 1988. B-mode ultrasound observations of bulls testes during breeding soundness examinations. *Theriogenology* 30, 1169-1175.
- França LR, Russell LD. 1998. The testis of domestic animals. In: Regadera J, Martínez-García F (eds). *Male reproduction. A multidisciplinary overview*. Churchill Livingstone, Madrid, Spain, Pp 197-219.
- Gábor G, Sasser RG, Kastelic JP, Mézes M, Falkay G, *et al*. 1998. Computer analysis of video and ultrasonographic images for evaluation of bull testes. *Theriogenology* 50, 223-228.
- Heath AM, Carson RL, Purohit RC, Sartin EM, Wenzel JG, *et al*. 2002. Effects of testicular biopsy in clinically normal bulls. *J Am Vet Med Assoc* 220, 507-512.
- Kastelic JP, Cook RB, Coulter GH. 1997. Contribution of the scrotum, testes, and testicular artery to scrotal/testicular thermoregulation in bulls at two ambient temperatures. *Anim Reprod Sci* 45, 255-261.
- Kastelic JP, Cook RB, Pierson RA, Coulter GH. 2001. Relationships among scrotal and testicular characteristics, sperm production, and seminal quality in 129 beef bulls. *Can J Vet Res* 65, 111-115.
- Ortavant R, Courrot M, Hochereau-de Reviers MT. 1977. Spermatogenesis in domestic mammals. In: Cole HH, Cupps PT (eds). *Reproduction in Domestic Animals*, Academic Press, New York, USA, Pp 203-227.
- Pastore AA, Toniollo GH, Cardilli DJ, Canola JC, Mercadante MEZ. 2015. Contribuição da ultrassonografia na avaliação andrológica de bovinos Nelore. *Rev Bras Reprod Anim* 39, 32-40.
- Pechman RD, Eilts BE. 1987. B-mode ultrasonography of the bull testicle. *Theriogenology* 27, 431-441.
- Pinho RO, Costa DS, Siqueira JB, Chaya AY, Miranda NT, *et al*. 2012. Testicular echotexture and seminal quality of young Montana Tropical

- Compound bulls classified as sound and unsound for breeding. *Rev Bras Zootec* 41, 1961-1965.
- Pinho RO, Costa DS, Siqueira JB, Martins LF, Chaya AY, *et al.* 2013. Correlation of sexual maturity stage with testicular echotexture in young Nelore bulls. *Acta Sci Vet* 41, 1161-1167.
- Silva AEDF, Kastelic JP, Unanian MM, Freitas AR, Cook RB. 1997. Ultrassonografia de machos Nelore na fase peri-puberal. *Rev Bras Reprod Anim* 21, 34-36.
- Singh J, Pierson RA, Adams GP. 1998. Ultrasound image attributes of bovine ovarian follicles and endocrine and functional correlates. *J Reprod Fertil* 112, 19-29.
- Singh J, Adams GP, Pierson RA. 2003. Promise of new imaging technologies for assessing ovarian function. *Anim Reprod Sci* 78, 371-399.
- Siqueira LGB, Viana JHM. 2006. Novas tecnologias em diagnóstico por imagem. *J Embrião* 28, 4-8.

